

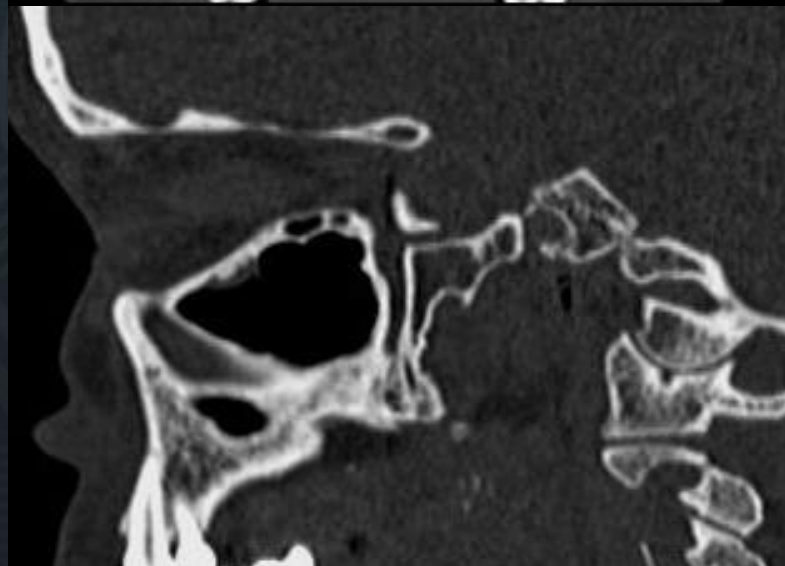
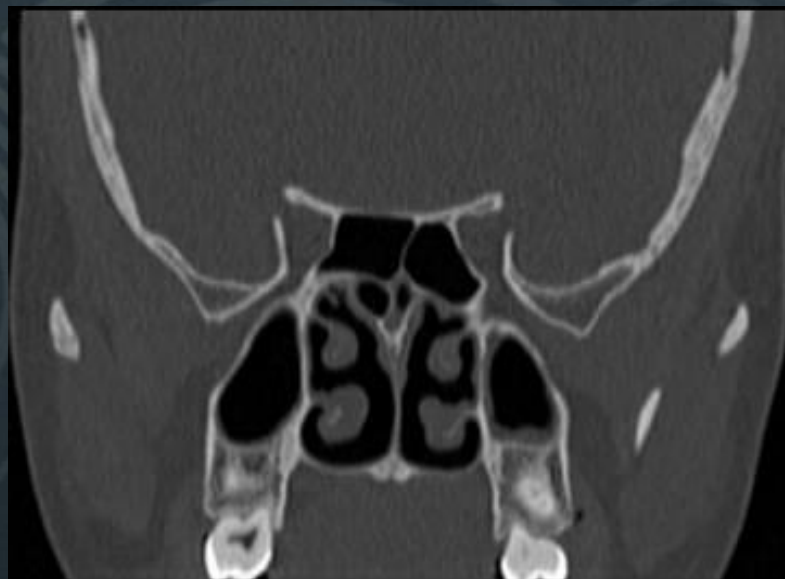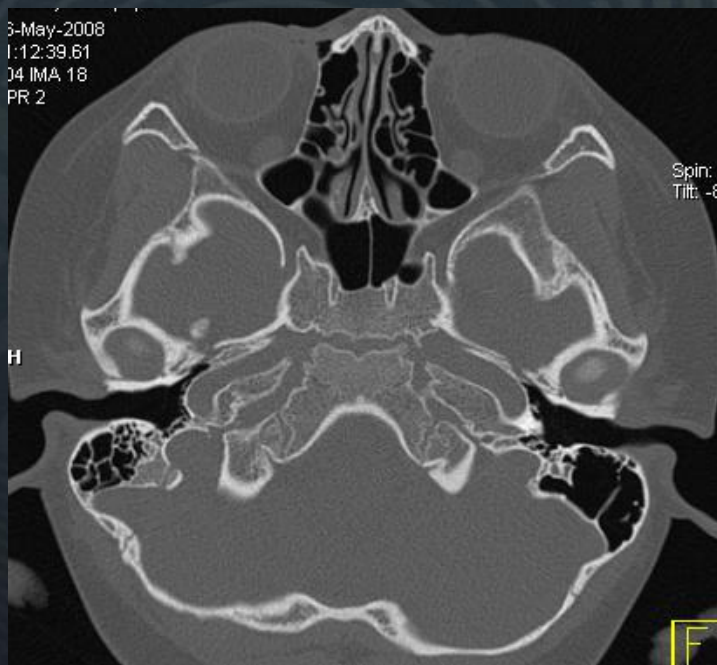# 翼腭窝解剖与临床

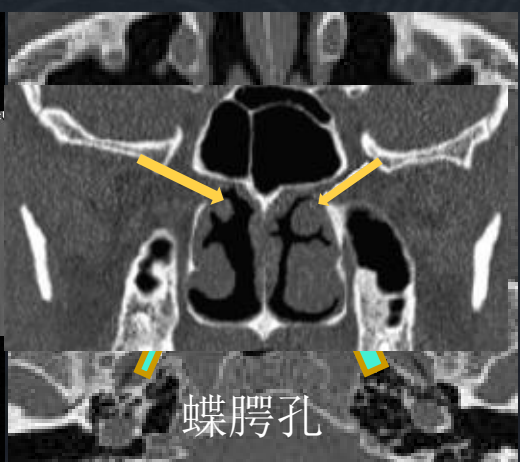
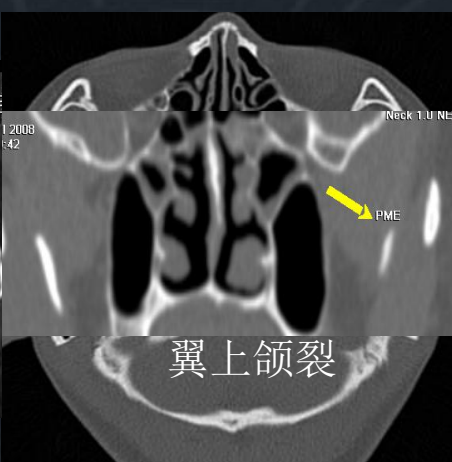
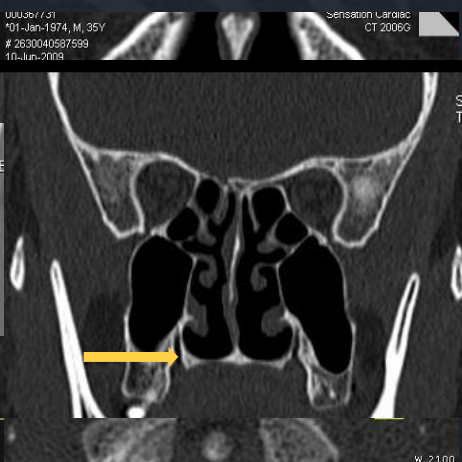
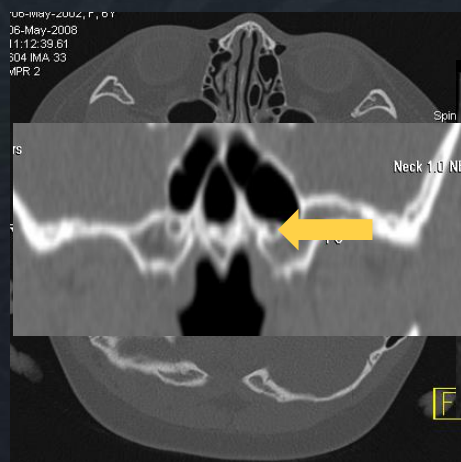
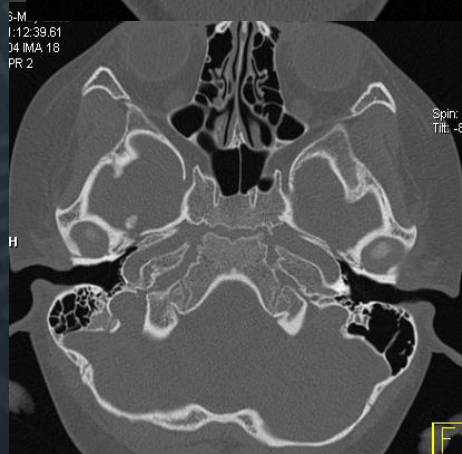
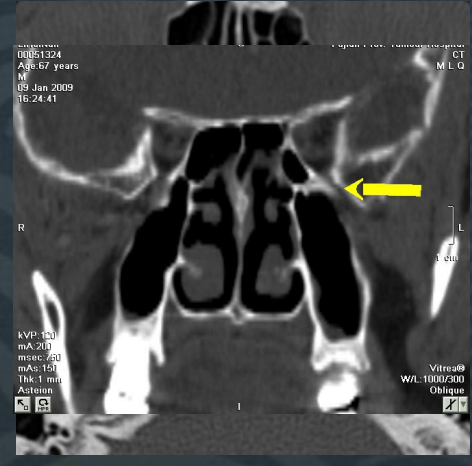
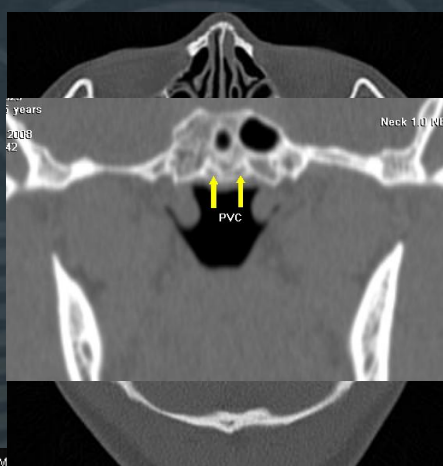
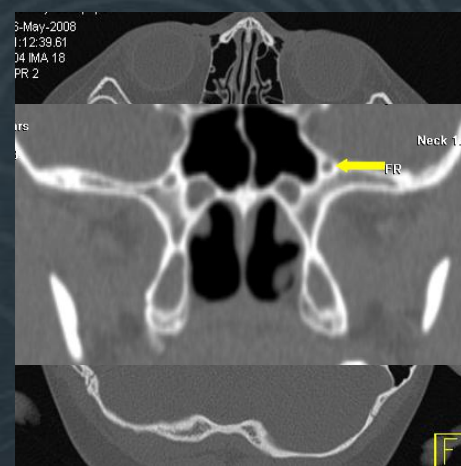
长治医学院医学影像学系 张琦

# 翼腭窝 (pterygopalatine fossa, PPF)

8通道7部位

内容：上颌神经、蝶腭神经节、上颌动脉等









# 孔道内容物

圆孔	上颌神经、导静脉	颅中窝
眶下裂	三叉神经上颌支	眼眶
蝶腭孔	蝶腭动脉、蝶腭神经	鼻腔
翼管	翼管动脉、翼管神经	破裂孔
腭鞘管	腭鞘动脉、咽神经	鼻咽
翼上颌裂		颞下窝
(上颌动脉及分支、下颌神经及分支、翼丛)		
腭大管	腭大动脉、腭大神经	口腔
腭小管	腭小神经和腭大动脉的分支	口腔

## 原发及继发病变的侵犯

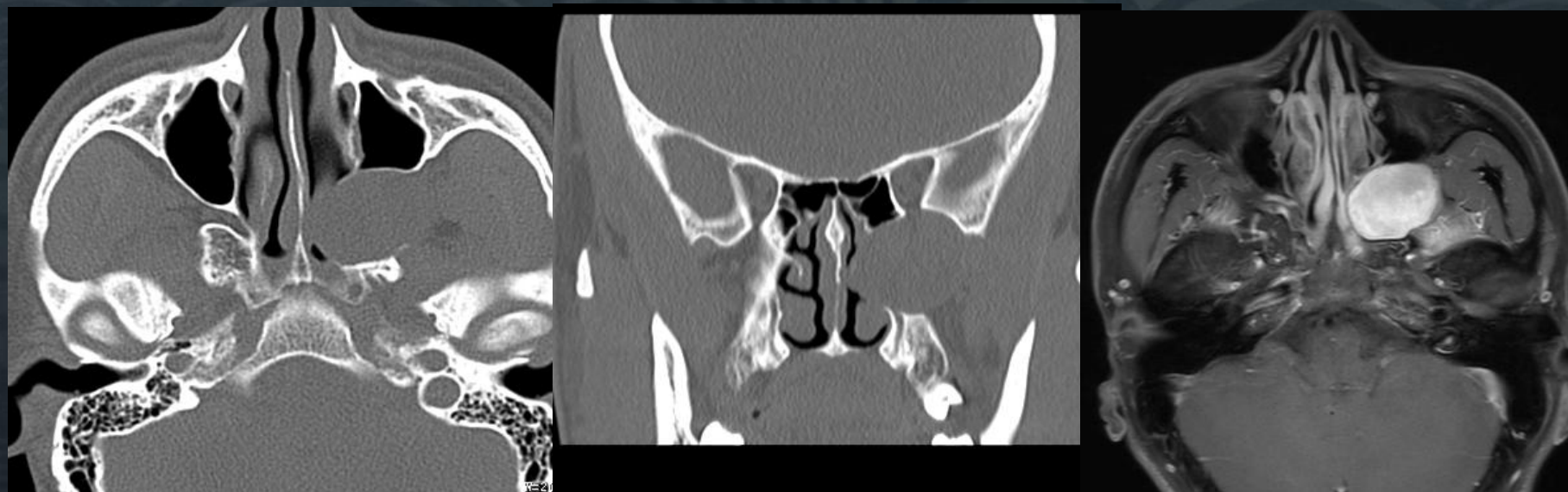容易累及翼腭窝的病变主要包括：

 眼眶炎性假瘤、侵袭性颅面部霉菌感染和颅底纤维化炎性假瘤

 上颌窦癌、鼻咽癌和鼻咽血管纤维瘤

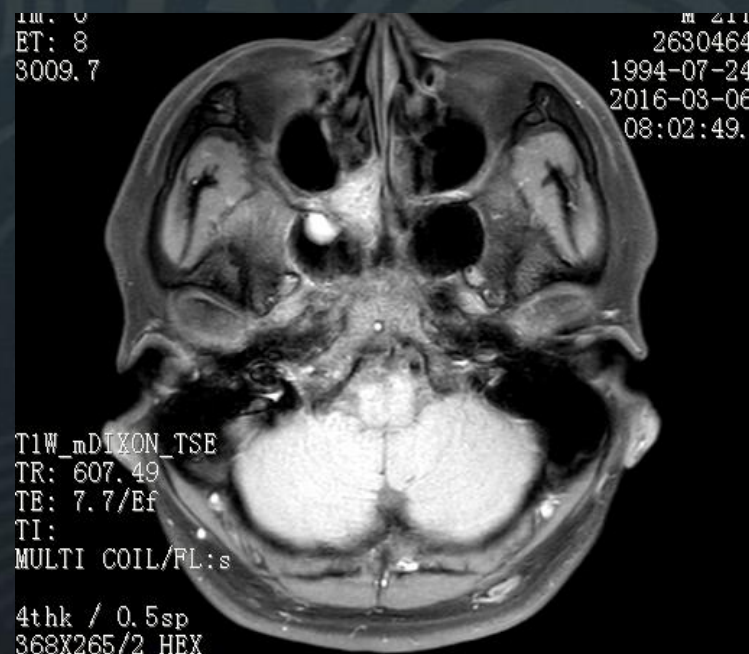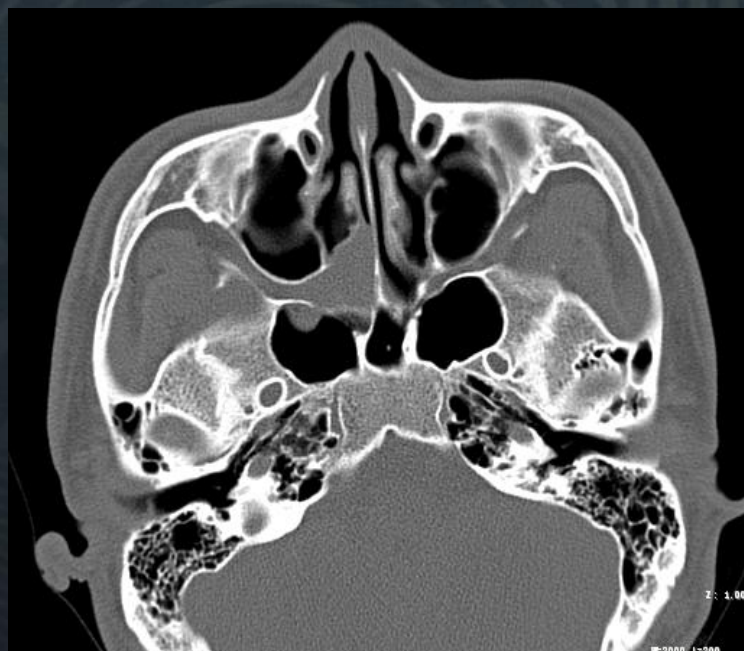 神经源性肿瘤、腺样囊性癌、黑色素瘤

# 神经源性肿瘤

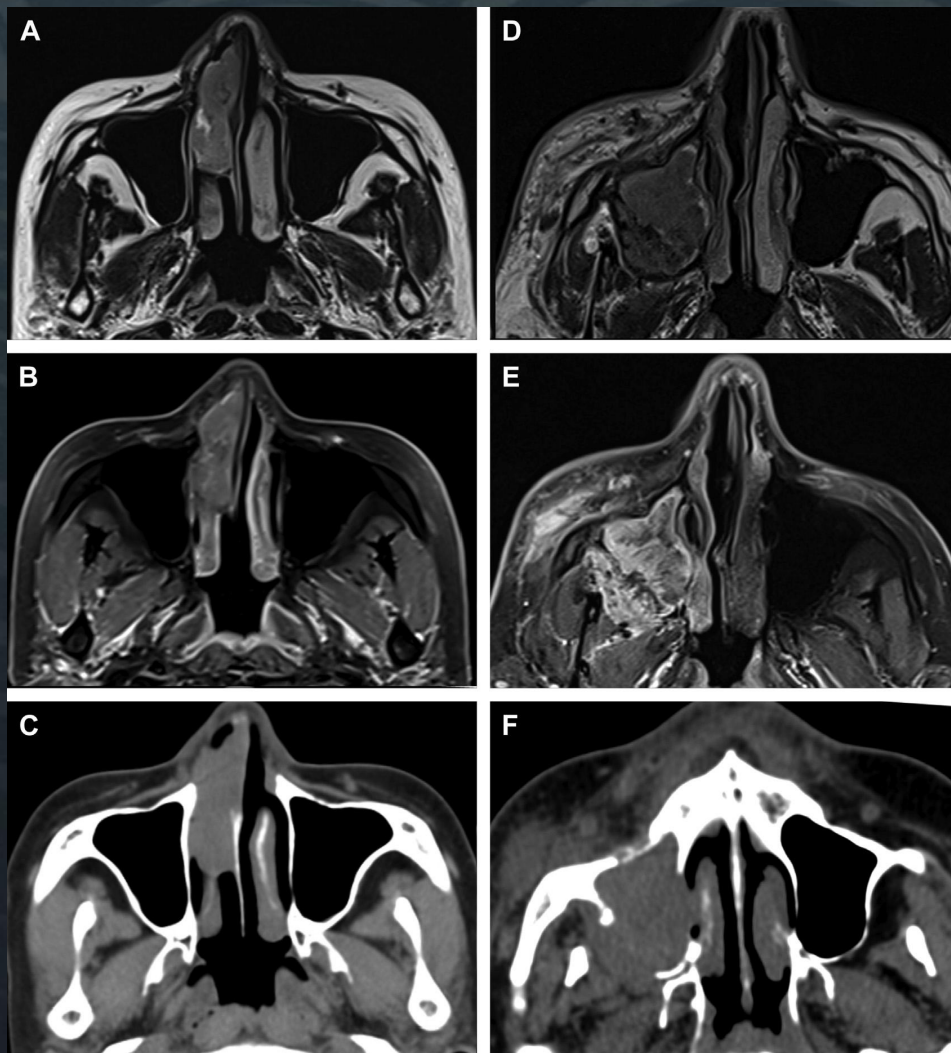




# 鼻咽纤维血管瘤

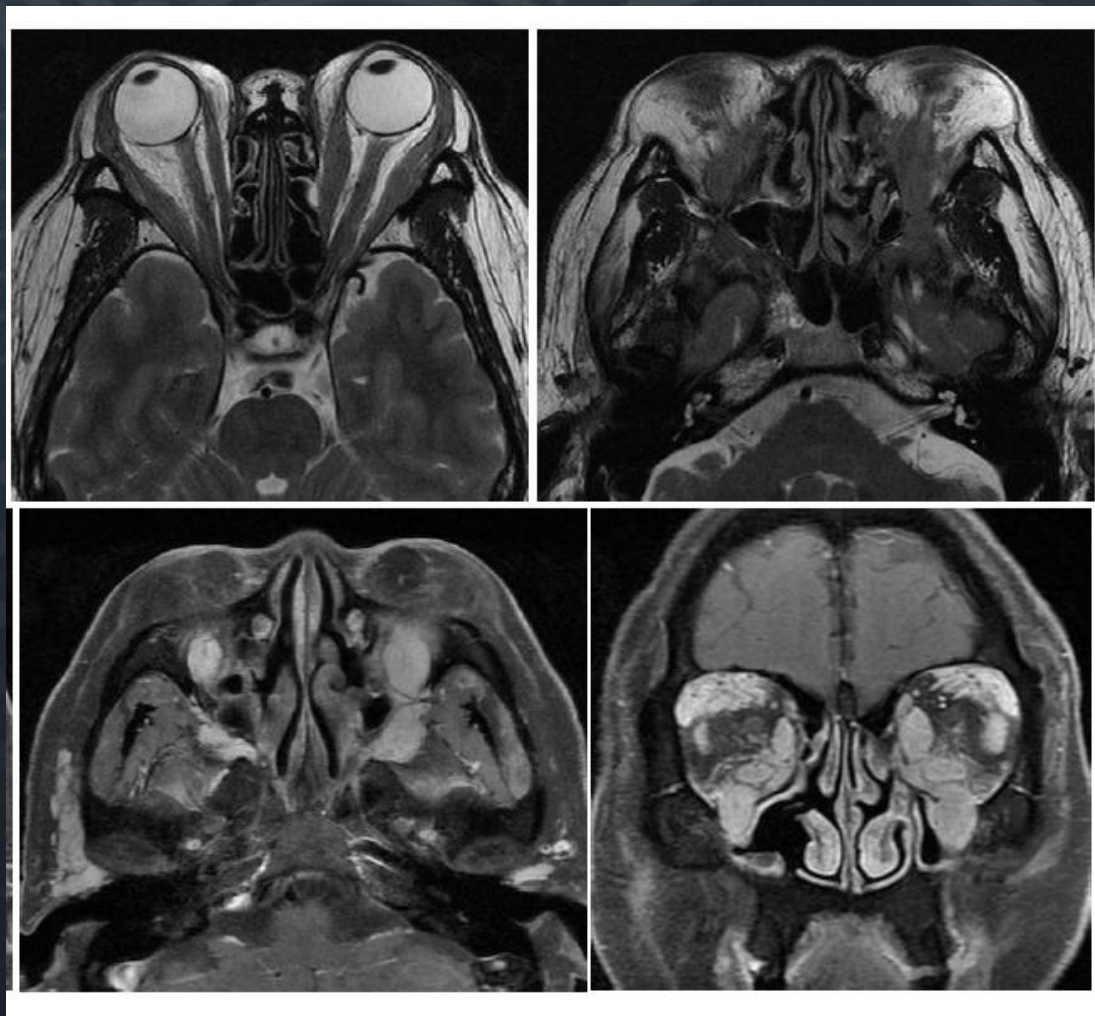


# 腺样囊性癌

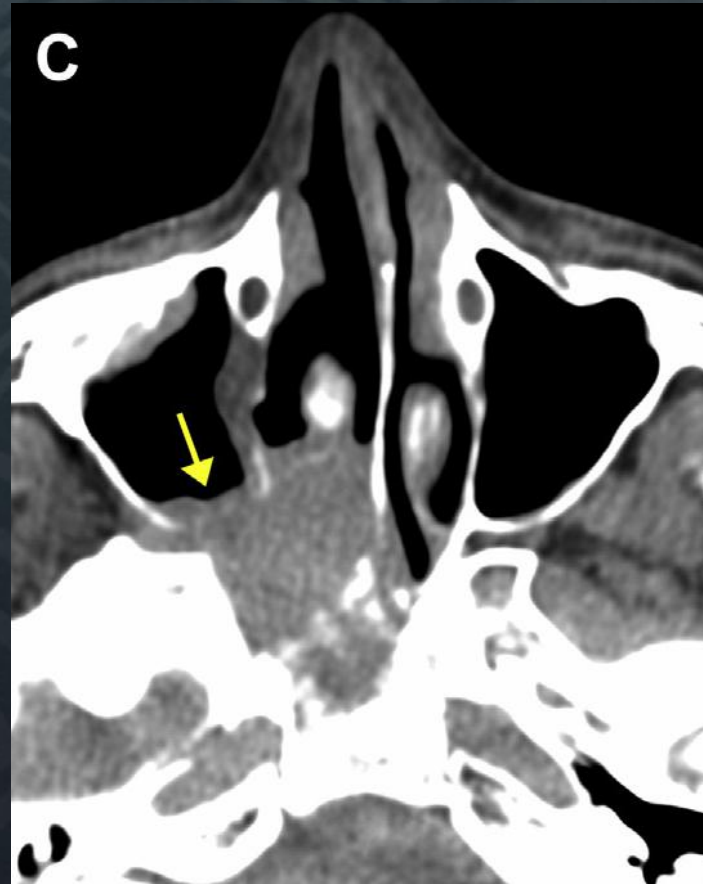




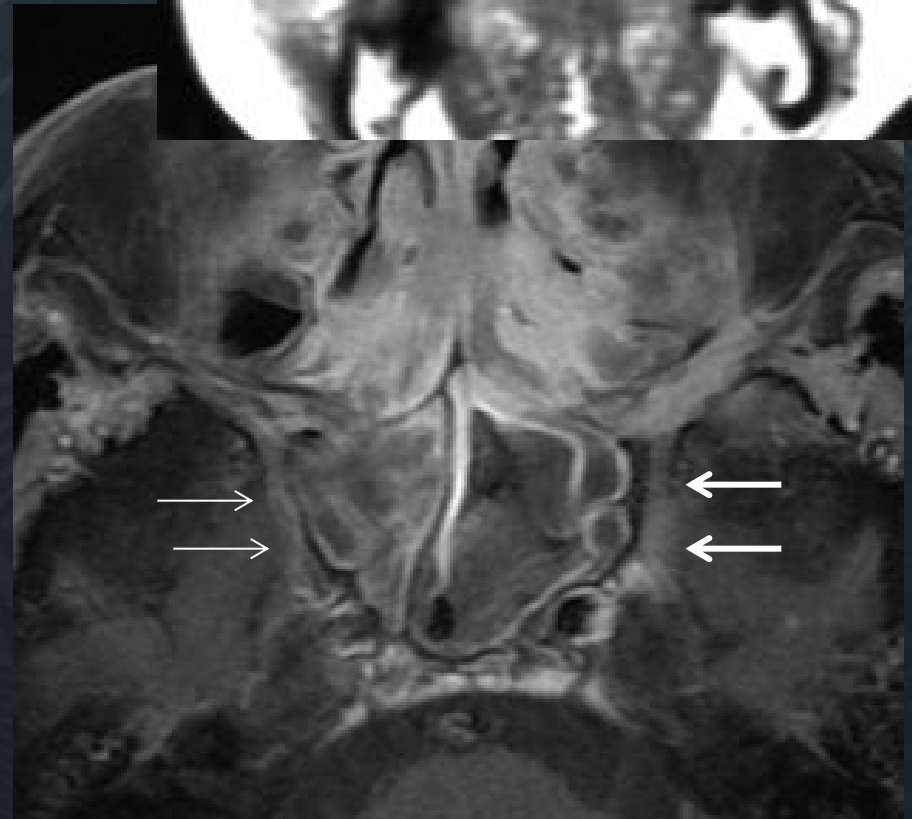
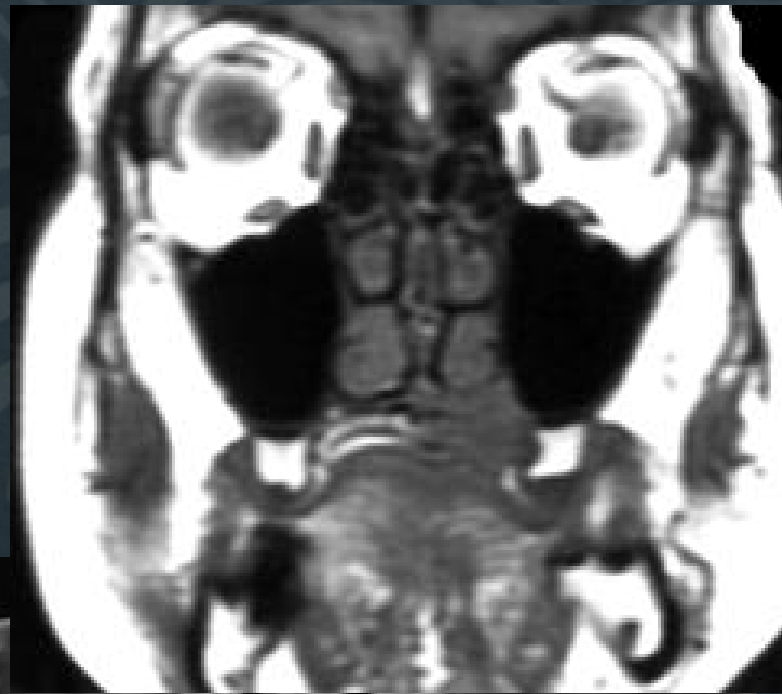
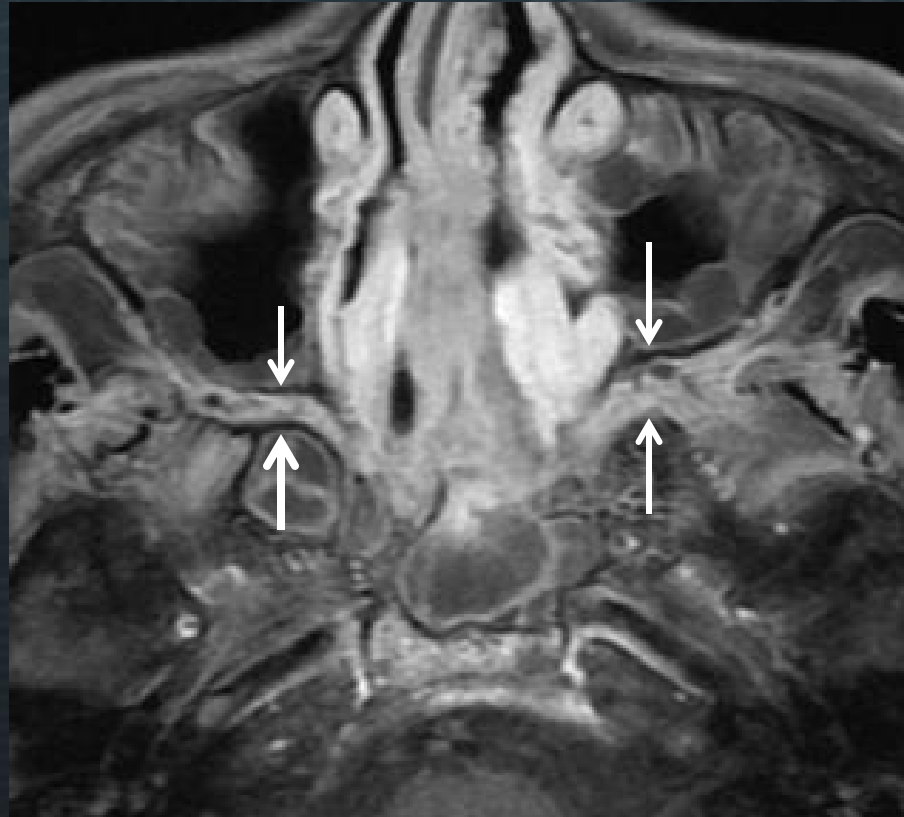IgG4



# 鼻咽癌



# 硬腭癌复发蔓延





The background features a dark blue field with a repeating pattern of concentric, semi-circular lines. A white dashed grid is overlaid on the image, consisting of a vertical line on the left and two horizontal lines that intersect to form a crosshair.

**THANKS**